



Morphometric Histological Variations in the Placenta of Normotensive and Pregnancy Induced Hypertensive Mothers

Falak Naz¹, Shazia Iftikhar¹, Zainab Rehman¹, Fatma Afridi¹, Shahsawar Afridi², Sarah Rehman³

¹Department of Anatomy, Khyber Medical College, Peshawar

²Ayub Medical College, Abbotabad.

³Department of Radiology, Fauji Foundation Hospital

ABSTRACT

OBJECTIVE: To study the macroscopic and microscopic alterations in placenta of pre-eclamptic mother using combination of morphometric and histological analysis.

METHODOLOGY: This was a retrospective cohort study carried out among pregnant women. The duration of this study was 6 months in a clinical setting of tertiary care hospital. A total of 50 freshly delivered normal normotensive (control group) and 50 pregnancy induced hypertensive (PIH) mothers (test group) of age limit 18-40 years were examined both grossly and histologically for placenta. Data was collected and analysed by SPSS version 21.

RESULT: On gross examination the morphometric parameters were significantly decreased in test group. Histological study showed the fibrinoid necrosis. Endothelial proliferation and calcification in the present study. The numbers of cotyledons were same in control (normotensive) and test (hypertensive) groups.

CONCLUSION: The study provided valuable insights into the histological and morphometric differences in the placenta of test and control group. The observed placental variations in test group were seen significantly different from control and it may influence on fetal health and pathophysiology of this condition in pregnant women. It will be more valuable if there will be further studies on molecular and genetic having direct implications on these changes and further clinical management among PIH mothers.

KEY WORDS: Pregnancy induced hypertension, Normotensive, Macroscopic, Cotyledons, Placentae, Microscopic, Normotensive, Apgar score, Birth weight, Fetal health.

*For Correspondence

Dr. Zainab Rehman

Department of Anatomy Khyber Medical College, Peshawar

Email: zainabiftikhar78@gmail.com

Submission date: 24th October, 2023

Acceptance date: 16th June, 2024

Publication date: 22nd June, 2024

INTRODUCTION

Human placenta is a unique and vital organ for growth, development and survival during intra-uterine life in maintaining a healthy pregnancy.¹ It helps in the exchange of nutrients, oxygen and waste products between fetal and maternal circulatory system.² It was recognized by Egyptian and named by Realdus Columbus in 1559.³ Embryo logically it is made up of fetal and maternal plates. Fetal plate is enclosed by amnion, made up of mesenchyme, avascular connective tissue and a layer of stratified squamous epithelium.⁴ Maternal plate consist of fibrinoids, extracellular matrix and blood clots, normally it is divided into 10 to 40 raised fragment called cotyledons. Placenta developed due to implantation, proliferation and differentiation of trophoblast.⁵ If placenta weight is less than 300gm represent hypoplasia and more than

700gm specifies hyperplasia.⁶

The gross and histological features of placenta effected by certain diseases such as hypertension, SLE and diabetes. As a result mother, fetus and new-born health can be effected.⁷ Placenta is just like a mirror of fetal and maternal health status shows changes under certain circumstances both macroscopically as well as microscopically. Placenta is involved in respiration, endocrine, immunological, excretion and nutritional functions.⁸

Placental examination provide knowledge about fetal growth in mother womb. Pregnancy induced hypertension is one of the leading cause of maternal, perinatal morbidity and mortality.⁹ Hypertensive disorders complicating pregnancy are usually related with placental insufficiency. In maternal hypertension the lumen of uterine vessels reduced, which results decrease

This Article may be cited as: Naz F, Iftikhar S, Rehman Z, Afridi F, Afridi S, Rehman S. Morphometric Histological Variations in the Placenta of Normotensive and Pregnancy Induced Hypertensive Mothers. Adv Basic Med Sci.2024; 8(1):17-22.DOI: <https://doi.org/10.35845/abms.2024.1.303>

blood flow among the intervillous spaces. Finally reduced utero-placental flow due to maternal vasospasm, results intra uterine growth retardation, fetal hypoxia, distress and finally death with placental anomalies.¹⁰ Worldwide about 12% of maternal demises are associated to Pregnancy induced hypertension.¹¹

Pregnancy induced hypertension is hypertension observed after 20 weeks of conception and fully recovered after delivery. It is also called toxemia of gestation and developed during second or third trimester. Incidence is approximately 1:1500. In our country maternal mortality is higher as compare to other third world countries.^{12,13} Pregnancy induced hypertension is one of leading cause of maternal mortality in Pakistan and very little studies are done. The present study was carried out to examine the macro, microscopic variations of placentae in Pregnancy induced hypertension regardless of intensity of disease and relate with the placentae of normal gestations.

METHODOLOGY

This was a retrospective cohort study which was carried out among pregnant women in a clinical setting of tertiary care Hospital Khyber Teaching Hospital and Anatomy Department of Khyber Medical College Peshawar from the duration of Jan 2021 to June 2021. The study was approved by the institutional review board (IRAB) before data collection. The selection criteria of study participants were pregnant women with age limit from 18-40 years and parity up to 8 month. Pregnant women with Diabetes Mellitus, hepato-renal diseases, twin pregnancy, Placenta Previa, abruption and cardiac diseases were excluded from this study.

Sample size for this study was calculated as 100 taking 95% confident interval and 5% precision by using online sample size calculator Open-EPI. After taking written consent from each study participants 100 placentae were taken after normal vaginal delivery, 50 from normotensive mothers with normal Blood pressure, no oedema, proteinuria and 50 from Pregnancy induced hypertensive mothers with Blood pressure above 140/90mmHg recorded at 6 hrs interval after 5 months of gestation with or without proteinuria, fits, oedema and history of unconscious. After delivery Placenta with membranes and umbilical cord 5 cm distal to its attachment taken, washed under tap water, membrane removed and dried with gauze.

Gross morphometric examination included shape, thickness (cm), weight (gm), and umbilicus for number of vessels were studied at Anatomy Department of Khyber Medical College Peshawar. For gross histological study the samples were put in 10% formalin solution for 48 hrs, to make it firm and make the furrows noticeable to count the cotyledons. For histological examination tissues were selected from margins at 12, 3, 6, and

9 clock locations. Haematoxylin and eosin sections were prepared for microscopic study of tissue sections. Student "t" test was applied for statistical significance between the means of different parameters of test and control groups. P value less than 0.05 was significant and SPSS version 22 was used for data analysis.

RESULTS

The study showed a higher trend of PIH pregnancy in older age (38%) as compared to normotensive pregnancy (20%) in 36-40 years participants. Lower age of pregnancy were found with increased normal cases, and the frequency of pregnant women in different partum stage were almost in same range 12 to 30% but high (50%) in P4-6 stage.

Age groups parity	No of cases	
	Control	PIH (test) group
18-21 years	13(26%)	6(12%)
22-26 years	10(20%)	12(24%)
27-35 years	17(34%)	13(26%)
36-40 years	10(20%)	19(38%)
Po	5(10%)	6(12%)
P1-3	12(24%)	15(30%)
P4-6	20(40%)	18(50%)
P7-8	10(20%)	11(22%)

Table 1: Demographic characteristics of study participants

Placental morphometric study showed that shape was round to oval and central attachment of umbilical cord in both groups. Gross Anatomical study showed that weight, surface area and infarction were significant different between control and test group $p < 0.05$. While statistically no significant change $p > 0.05$ was observed in central thickness and numbers of cotyledons in the mentioned groups. The mean weight of new-born in study group was significantly decreased than in control group (Table 2, 3).

Variables	Control group	PIH group	p value
Mean Placental weight (gm)	578±50.64	380±70.2	< 0.0001
Mean placental volume (cm) ³	576.9±80.5	399±60.5	< 0.0001
Mean placental area (cm) ²	284.6±31.2	228.4±35.4	< 0.0001

Table 2: Morphometric study of the placenta of study participants

Variables	Control group	PIH group	p value
Numbers of Cotyledons mean \pm SD	19.81 \pm 0.98	20.01 \pm 0.82	P value
Infarction	8%	28%	0.031
Numbers of Vessels in Umbilicus	Same	Same	NA
Central Thickness	2.91 \pm 0.41	2.89 \pm 0.32	0.7863

Table 3: Gross features of Placentae of study participants

Histological study showed that thickness of the sub trophoblastic basement membrane was greater in placenta of test group than in the control group. Similarly the mean number of chorionic villi showed more collagen in PIH group than the

Normotensive, while statistically the change was insignificant. PIH Placentae showed more calcification as compared to control group (Table 4).

Parameters	Control group	Test group	P value
Fibrinoid necrosis	3%	18%	0.01
Fibrosis	36%	10%	0.865
Calcification	29%	6%	0.03
Endothelial growth	13%	2%	0.04
Syncytial Knots	34%	14%	0.654
Acute Atherosclerosis	2%	18%	0.03

Table 4: Histological Features of Placentae of study participants


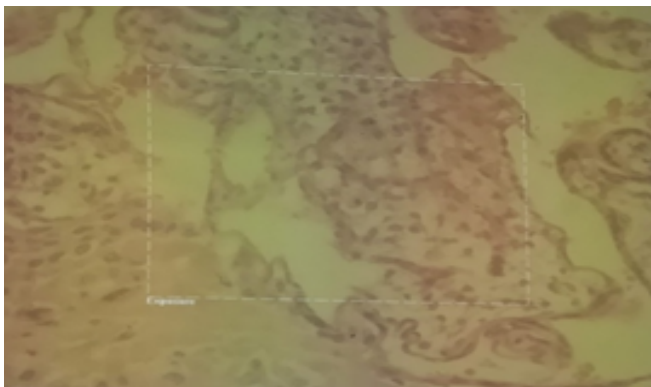
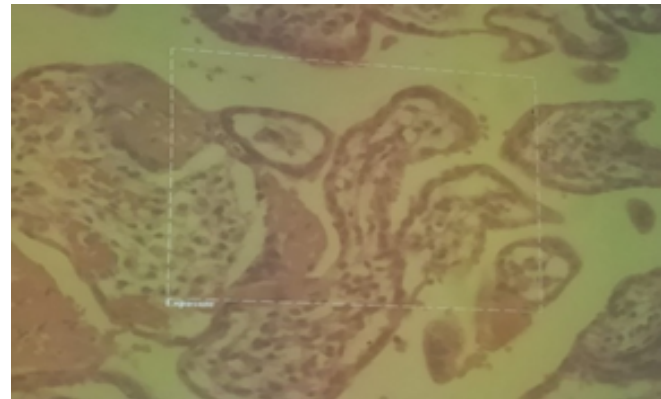
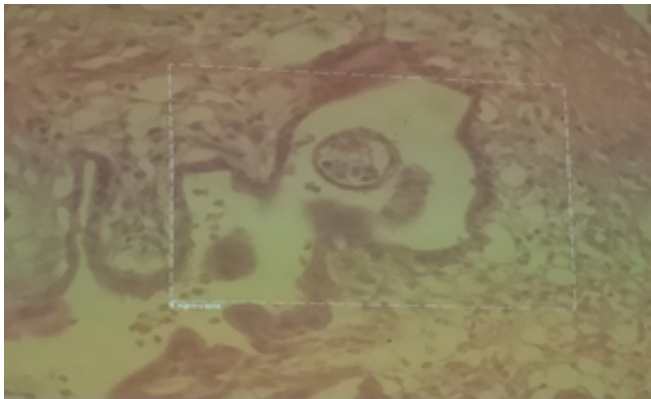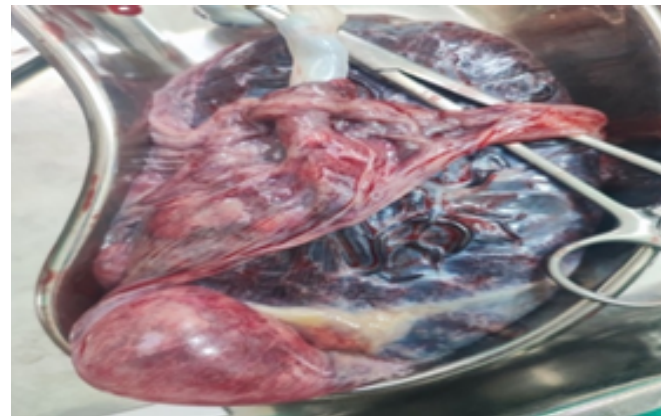
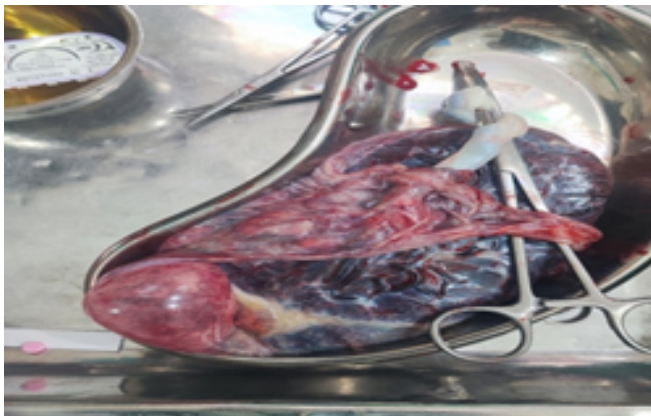


Fig 1: Gross and histological features of placenta of normal and pregnancy induced hypertensive patients

DISCUSSION

This study demonstrate significant histological and morphometric variations in the placenta of pregnancy-induced hypertensive mothers compared to normotensive pregnancies. These changes in placenta are due to hypertension and considered as the structural and functional changes and are associated with high implications for fetal development and maternal health.

Reduced placental size and thickness, along with altered villous morphology and vascular development, indicate compromised blood flow and nutrient exchange in PIH placentas.¹⁴ Due to hypertension inflammatory changes happened in placentas during pregnancy. Placenta is really particular organ of pregnancy as fetal growth and development depends on it.¹⁵

Mean placental weight in test group was less as compared to control group. Our study findings was consistent with findings of General Hospital of Massachusetts pathology deptt, Sultana S, et al¹⁶, and few other studies.^{17,18} The placental, fetal weight showed fetal and placental growth. The low placental weight was concerned with low birth weight due to insufficient uteroplacental blood flow in test group. Our study showed the mean birth weight of babies born to control group was significantly low than control group^{19,20}, which is consistent with findings of two other studies. In Pakistan perinatal mortality rate is 50-60/1000 associated with low birth weight. PIH contribute for 3-4 fold perinatal mortality as proved in a systemic review of middle income countries data.²¹ The mean placental volume also less in PIH group than the normotensive group which was similar to another study finding.²²

The number of cotyledons were approximately similar in both groups and there was no statistically significant change observed. The same findings were found in another study where cotyledons numbers were same in both group.²³

According to Zeek and Assali placental infarction is the area of ischemic necrosis of a set of villi due to their insufficient blood supply (thrombosis of spiral arteriole) in deciduas.²⁴ Fox found the incidence of placental infarction higher in PIH.²⁵ In the present study placental infarction was also found in PIH group, so our study consistent with his study. Atherosclerosis is taken as part of decidual vasculopathy and is related with hypertension.

Acute atherosclerosis is a lesion limited to blood vessels that have not been altered by the normal adaptive processes of implantation. Similar vascular lesions are noted in placenta of problematocal of diabetes, SLE and hypertension.²⁶ In our study fibroid necrosis observed significant in test group as compare to control group which is consistent with the work done in General hospital of Massachusset. Normally calcification of placenta shows aging

process and reduced utero-placental perfusion.²⁷

Calcification occurred in villi and their basement membrane, results narrow lumen and uteroplacental insufficiency. The pathological maturation is seen in PIH group, leads to intrauterine growth retardation, fetal distress, demise and preterm delivery. In the present study calcification was significantly noted in test group which is consistent with the study where it was found that calcification was prominent in test group.^{28,29}

LIMITATIONS OF THE STUDY: This study was carry out in a single public sector tertiary care hospital with a limited sample size due to which generalization of this study findings to entire Pakistani population is not possible. Due to limited time and budget prospective histological study of single patients at multiple stage of pregnancy was not possible therefore we could not obtained much targeted results.

CONCLUSION

The study provided valuable insights into the histological and morphometric differences in the placenta of test and control group. The observed placental variations in test group were seen significantly different from control and it may influence on fetal health and pathophysiology of this condition in pregnant women. It will be more valuable if there will be further studies on molecular and genetic having direct implications on these changes and further clinical management among PIH mothers.

CONFLICTS OF INTEREST: The author declare no conflict of interest.

FUNDING: It was non-funded research work.

REFERENCES

1. Kaufman MR and Brown TL. AMPK and placental progenitor cells. AMP-activated Protein Kinase. 2016; 73-9.
2. Melbourne A, Aghwane R, Sokolska M, et al. Separating fetal and maternal placenta circulations using multiparametric MRI. Magnetic resonance in medicine. 2019; 81: 350-61.
3. Keche HA and Kazi S. Correlation of histology of placenta with fetal outcome in pregnancy induced hypertension. National Journal of Clinical Anatomy. 2018; 7: 24-31.
4. Nanci A. Ten Cate's Oral Histology-e-book: development, structure, and function. Elsevier Health Sciences, 2017
5. Dahlstrom JE, Subramaniam A and Faye-Petersen OM. Maternal Vascular Malperfusion and Associated Maternal Diseases. Benirschke's Pathology of the Human Placenta.

- 2022;507-54.
6. Ghani N and Yadav K. Comparative Study on Macroscopic Morphology of Human Placenta in Preterm, Term & Post Term Pregnancy. *International Multispecialty Journal of Health*.2018;4: 109-14.
 7. Starikov R, Inman K, Chen K, et al. Comparison of placental findings in type 1 and type 2 diabetic pregnancies. *Placenta*. 2014;35: 1001-6.
 8. Staud F and Karahoda R. Trophoblast: The central unit of fetal growth, protection and programming. *The international journal of biochemistry & cell biology*. 2018; 105:35-40.
 9. Vayssière C, Sentilhes L, Ego A, et al. Fetal growth restriction and intra-uterine growth restriction: guidelines for clinical practice from the French College of Gynaecologists and Obstetricians. *European journal of obstetrics & gynecology and reproductive biology*. 2015; 193:10-8.
 10. Rajan B. Patterns of Antenatal Medication Use, its Determinants, and Outcomes in Pregnancy Among Women Admitted in the Obstetrics Wards of a Tertiary Care Hospital: A Cross Sectional Study. *Rajiv Gandhi University of Health Sciences (India)*, 2019.
 11. Lo JO, Mission JF and Caughey AB. Hypertensive disease of pregnancy and maternal mortality. *Current Opinion in Obstetrics and Gynecology*.2013; 25: 124-32.
 12. Toshimitsu M, Nagamatsu T, Nagasaka T, et al. Increased risk of pregnancy-induced hypertension and operative delivery after conception induced by in vitro fertilization/intracytoplasmic sperm injection in women aged 40 years and older. *Fertility and Sterility*. 2014; 102: 1065-70.e1.
 13. Fakhrunissa WM, Naqvi R, Jabbar S, Zaidi SA and Fatima ST. Pregnancy induced hypertension among pregnant women delivering in a tertiary Care Centre. *Pakistan Journal of Medical & Health Sciences*. 2022; 16: 709-.
 14. Sun C, Groom KM, Oyston C, Chamley LW, Clark AR and James JL. The placenta in fetal growth restriction: what is going wrong? *Placenta*. 2020; 96: 10-8.
 15. Ilekis JV, Tsilou E, Fisher S, et al. Placental origins of adverse pregnancy outcomes: potential molecular targets: an Executive Workshop Summary of the Eunice Kennedy Shriver National Institute of Child Health and Human Development. *American journal of obstetrics and gynecology*.2016; 215: S1-S46.
 16. Asif HM, Sultana S, Akhtar N, Rehman JU and Rehman RU. Prevalence, risk factors and disease knowledge of breast cancer in Pakistan. *Asian Pacific journal of cancer prevention*.2014; 15:4411-6.
 17. Gibbs I, Leavey K, Benton SJ, Gynspan D, Bainbridge SA and Cox BJ. Placental transcriptional and histologic subtypes of normotensive fetal growth restriction are comparable to preeclampsia. *American Journal of Obstetrics and Gynecology*.2019; 220: 110.e1-.e21.
 18. Rohini P, Siddharth T, Fathima A and Dhiren P. Human Placentae in Pregnancy-induced Hypertension-A Histologic and Morphometric Analysis. *Int J Anat Appl Physiol*.2018;4: 95-8.
 19. Talpur RA, Siddiqui S, Khowaja S, Noor N, Baloch MS and Qazi MM. Histomorphometric Variations of the Placenta in Normal and Hypertensive Pregnancies. *Journal of Islamabad Medical & Dental College*. 2020; 9: 242-8.
 20. Salmani D, Purushothaman S, Somashekara SC, et al. Study of structural changes in placenta in pregnancy-induced hypertension. *Journal of natural science, biology, and medicine*. 2014;5: 352.
 21. Nigam JS, Misra V, Singh P, Singh P, Chauhan S and Thakur B. Histopathological study of placenta in low birth weight babies in India. *Annals of Medical and Health Sciences Research*.2014; 4: 79-83.
 22. Kinshella M-LW, Omar S, Scherbinsky K, et al. Maternal dietary patterns and pregnancy hypertension in low-and middle-income countries: a systematic review and meta-analysis. *Advances in Nutrition*. 2021; 12: 2387-400.
 23. Karmakar M, Kumar S, Chattopadhyay S, Kar S, Vaid L and Sen S. A study on the morphology and the morphometry of the human placenta and its clinical significance in rural population in Eastern India. *Asian Pacific Journal of Health Science*.2018; 5: 202-9.
 24. Elamin AA, Ahmed MNM, El Elhaj A, et al. Vicissitudes in the placental cotyledon number in a singleton pregnancy with gestational diabetes. *International Journal of Applied and Basic Medical Research*. 2022; 12: 24.
 25. Kartha S, Poothiode U and Jayalakshmy P. Placental pathology in pregnancy induced hypertension. *Journal of Evolution of Medical and Dental Sciences*. 2014; 3: 9272-9.
 26. Matthews KC, Fox NS and Rebarber A. The association between placental histopathology, fetal growth restriction, and preeclampsia in twin pregnancies. *American Journal of Perinatology*.2019; 38: 784-90.
 27. Staff AC, Fjeldstad HE, Fosheim IK, et al. Failure of physiological transformation and spiral artery atherosclerosis: their roles in preeclampsia. *American journal of obstetrics and gynecology*. 2022; 226: S895-S906.

28. Moran MC, Mulcahy C, Zombori G, Ryan J, Downey P and McAuliffe FM. Placental volume, vasculature and calcification in pregnancies complicated by pre-eclampsia and intra-uterine growth restriction. *European Journal of Obstetrics & Gynecology and Reproductive Biology*. 2015; 195:12-7.

29. Edzie EKM, Dzefi-Tettey K, Brakohiapa EK, et al. Assessment of the clinical presentations and ultrasonographic features of uterine fibroids in adult Africans: A retrospective study. *Oman Medical Journal*. 2023;38:e459.

CONFLICT OF INTEREST

Author declared no conflict of interest

GRANT SUPPORT & FINANCIAL DISCLOSURE

Author declared no specific grant for this research from any funding agency in the public, commercial or non-profit sectors

AUTHORS CONTRIBUTIONS

FN: Conception, Design of the work, Data collection, and Drafting, Reviewed, Final approval, Agreement to be accountable.

SI: Conception, Design of the work, Acquisition, Data Analysis, and Drafting, Reviewed, Final approval, Agreement to be accountable.

ZR: Conception, Design of the work, Interpretation of data for the work, and Drafting, Reviewed, Final approval, Agreement to be accountable.

FA: Conception, Design of the work, Data collection, and Drafting, Reviewed, Final approval, Agreement to be accountable.

SA: Conception, Design of the work, Acquisition, Data Analysis, and Drafting, Reviewed, Final approval, Agreement to be accountable.

SR: Conception, Design of the work, Data collection, Data analysis and Drafting, Reviewed, Final approval, Agreement to be accountable.



This is an Open Access article distributed under the terms of the Attribution Non-Commercial 4.0 International