



A Cross-sectional Study to Analyse the Anthropometric Measurements of Mental Foramen of Dry Human Mandibles

Jawaria Aslam Awan¹, Ambreen Surti^{1*}, Ayesha Saba Naz¹, Aisha Qamar¹, Rashid Ahmed²

¹Department of Anatomy, Bahria University Health Sciences Campus, Karachi

²Department of Anatomy, Baqai Medical University, Karachi

ABSTRACT

OBJECTIVE: To observe shape, size and position of mental foramen in association with clinically relevant landmarks of mandible.

METHODOLOGY: The distance from different landmarks such as mandibular symphysis, crest of the alveolar bone, ramus of mandible (posterior border) and mandibular base were measured with the help of a digital Vernier caliper for calculating mental foramen's size. Each measurement was taken 3 times with an interval of 3 days. Pearson's correlation was used to observe association between measurements of "mental foramen."

RESULTS: Frequently occurring shape of mental foramina was oval. Commonest position was found as position IV (50%), where it was present on an axis passing longitudinally through the 2nd premolar. Weak positive correlation was observed on right side between vertical diameter (VD) as well as Horizontal diameter (HD), however, weak negative correlation was noted between the VD and HD on the left side. But a positive correlation was also seen in the VD and HD.

CONCLUSION: There are variations in shape and size, as well as position of "mental foramen" in our community. Knowledge in regards to these variations is essential for accurate localization of mental foramen which in turn is important both in forensic medicine as well as in clinical application.

KEY WORDS: Mental foramen, Variations, Localization, Anthropometry, Mandibles

*For Correspondence

Dr. Ambreen Surti

Assistant Professor,
Department of Anatomy, Bahria
University, Health Sciences
Campus, Karachi, Pakistan

Email: ambreensurti@yahoo.com

Submission date: 7th October 2022

Acceptance date: 26th June 2023

Publication date: 26th June 2023

INTRODUCTION

"Mental foramen" (MF), is an extremely important opening which is cone-shaped located bilaterally on the anterior surface of mandible's body, typically beneath premolars.¹ It gives passage to a branch of "Inferior alveolar nerve", responsible for providing sensory supply to lower lip, teeth and lower part of the face.² MF is a vital landmark for the purpose of diagnosis and performing clinical procedures. It is commonly felt while delivering anaesthesia for mental nerve block, surgical cutting of the bone in osteotomies needed for different types of oro-facial and orthognathic surgeries, and dental implants' placement³. It is crucial to correctly localize its position so as to avoid trauma to "mental nerve and vessels" during these procedures. Therefore, its knowledge with respect to its size, shape and position is imperative for performing dental procedures.¹ The radiographic and anatomic shape, size, symmetry and location of mental foramen have been demonstrated in multiple studies by

different authors.⁴ A large number of variations have also been observed regarding the position of MF. It can be positioned around the apical area of lower premolars, or under second premolar's apex.⁵ MF was most frequently located between the 1st and 2nd premolars in research carried out in North American whites⁶ and Bangladeshis⁷. However, studies done in the Malawian population⁸ showed that it was located in line with the second premolar. Aims: Studies in specific populations are necessary to locate exact position of mental foramen anatomically. This precise localisation is essential to avoid damage to mental nerve during different minor and major oral & maxillofacial surgeries as well as for successful mental nerve blocks and anaesthesia. Just as efficient attainment of anaesthesia is vital for a painless smooth completion of oral procedures, in the same way prevention of damage to mental nerve is crucial to not to disturb QOL (quality of life) of patient. Therefore, the current study was undertaken to bridge the gaps in the knowledge regarding this.

This Article may be cited as: Awan AJ, Surti A, Naz SA, Qamar A, Ahmed R. A Cross-sectional Study to Analyse the Anthropometric Measurements of Mental Foramen of Dry Human Mandibles. Adv Basic Med Sci. 2023;7(1):03-07. DOI: <https://doi.org/10.35845/abms.2023.1.232>

METHODOLOGY

It was a cross-sectional study carried out on 30 dry human mandibles (60 mental foramina). After obtaining ethical approval (ERC 60/2022), dry mandibles were obtained by non-probability purposive sampling from Bahria University Health Sciences Campus, Karachi and Baqai University. Mental foramina of each dry mandible were analysed on both sides. The distance from different landmarks such as mandibular symphysis, crest of the alveolar bone, ramus of mandible (posterior border) and base of the mandible⁹ were assessed with the help a digital Vernier calliper for calculating mental foramen's size (Figure 1a & b).

"AC": "Distance from alveolar crest to upper margin of MF"

"BD": "Distance from lower border of mandible to lower margin of mental foramen"

"AB": "Distance from alveolar crest to lower border of mandible.

"VD": "Vertical diameter of foramen = $B - (C + BD)$ "

"WY": "Distance from symphysis menti to medial margin of MF"

"XZ": "Distance from posterior border of ramus of mandible to lateral margin of MF"

"WX": "Distance from symphysis menti to posterior border of ramus of mandible" a "HD": "Horizontal diameter of foramen = $WX - (WY + XZ)$ "

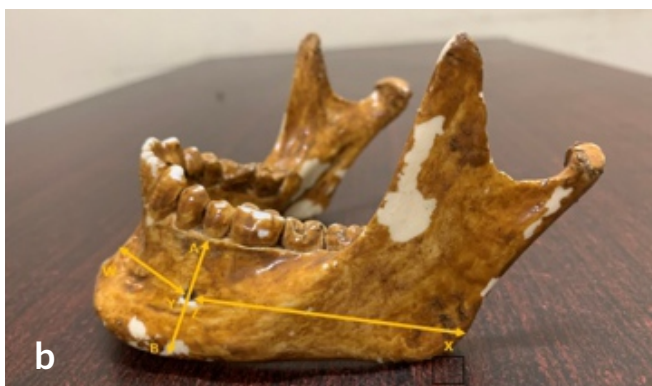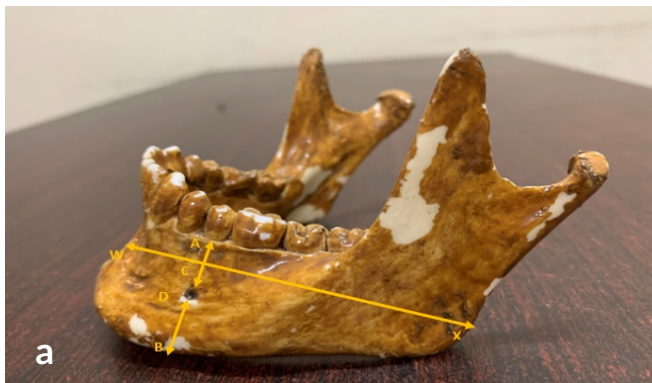


Figure 1: Showing the anatomical landmarks used for measuring the location of mental foramina

Figure 1: Showing the anatomical landmarks used for measuring the location of mental foramina. The position¹⁰ was also noted by observing the following parameters:

"I". "The MF situated on longitudinal axis passing between canine and 1st premolar"

"II". "The MF situated on longitudinal axis passing through the first premolar"

"III". "The MF situated on longitudinal axis passing between 1st and 2nd premolars"

"IV". "The MF situated on longitudinal axis passing through 2nd premolar"

"V". "The MF situated on longitudinal axis passing between 2nd premolar and 1st molar"

"VI". "The MF situated on longitudinal axis passing through 1st molar"

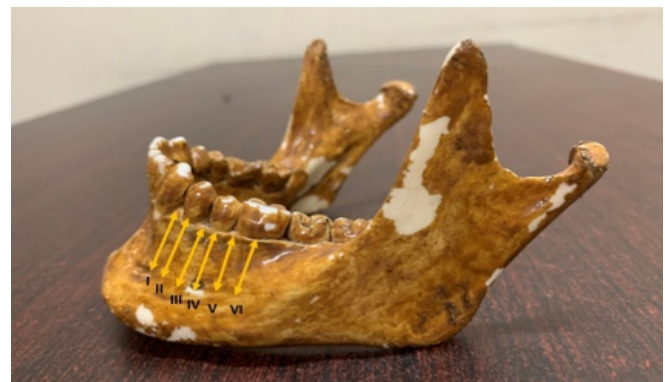

Figure 2: Showing the longitudinal landmarks used for measuring the location of mental foramina

Each measurement was taken 3 times with interval of 3 days and were recorded by a single investigator in order to reduce intra observer error. Data was analysed using "Statistical Package for the Social Sciences (SPSS) version 23". The results were presented as percentages and means with standard deviation. Pearson's correlation was used to see association between measurements of mental foramen on right and left sides.

RESULTS

Thirty dry mandibles (22 females and 8 males) were assessed to observe the shape, size and position of mental foramen. The most frequent shape noted in the mandibles was oval (66.7%). Oval shape was present on both sides commonly as compared to the round shape which was observed in 10 mandibles (33.3%). The most predominant position of the "mental foramen" was noted as "position IV" (50%), where it was present on the axis passing longitudinally through the 2nd premolar. However, no foramen was found in position I as shown in Figure 3.

It was observed that the mean VD of oval MF on left and right side was 2.62mm and 2.61mm respectively. "Mean" VD of round

“MF on the right and left sides” was 2.64mm and 2.63mm respectively.

On right side, HD of oval MF was 5.63mm while on left side it was 5.76mm. HD of round MF noticed on right side was 5.65mm while on the opposite side it was, 5.49mm. (Figure 1).

Diameter	Side	Shape	n	Mean±SD
VD	Right	Oval	20	2.62±0.08
HD			20	5.63±0.39
VD		Round	10	2.64±0.08
HD			10	5.65±0.54
VD	Left	Oval	20	2.61±0.10
HD			20	5.76±0.47
VD		Round	10	2.63±0.06
HD			10	5.49±0.51

Table 1: Vertical and horizontal diameters of round and oval shapes of mental foramina on right and left sides (n= 30). VD: “Vertical diameter of mental foramen” HD: “Horizontal diameter of mental foramen”

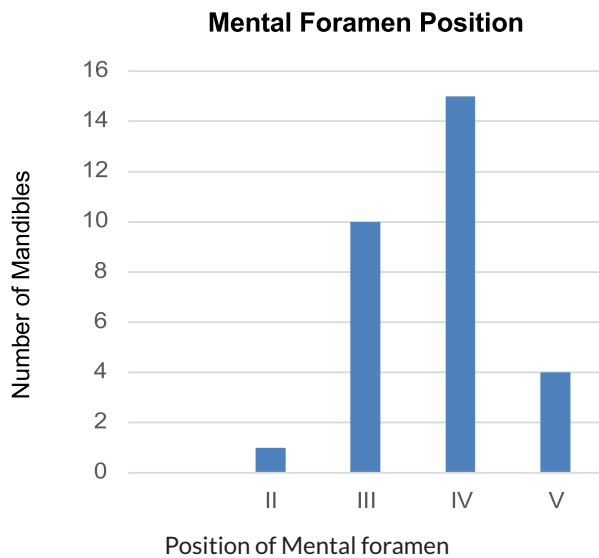


Figure 3: showing frequency of different positions of mental foramina

In terms of mental foramen positions, the majority of them were found in position IV (15), followed by position III (10), position V (4), and position II (1). The position I revealed none of the foramen.

Males had a greater occurrence of position IV, followed by position III, position V and none was found in position II and I, whereas females had a higher incidence of position IV, followed by position III, position V, position II. (Figure 4)

Pearson's correlation was applied to observe correlation and strength of association between vertical and horizontal

diameter with each other as well as on left and right side. A weakly negative correlation ($r = -0.143$) was noted in between VD and HD on left side while a weakly positive correlation ($r = 0.119$) was noted in between the two diameters on right side. A positive correlation was also observed in VD on right and left side ($r = 0.529$) indicating that if VD increases on right side, it will also increase on the left side. A similar positive correlation was also observed in HD on both sides as shown in figure 5.

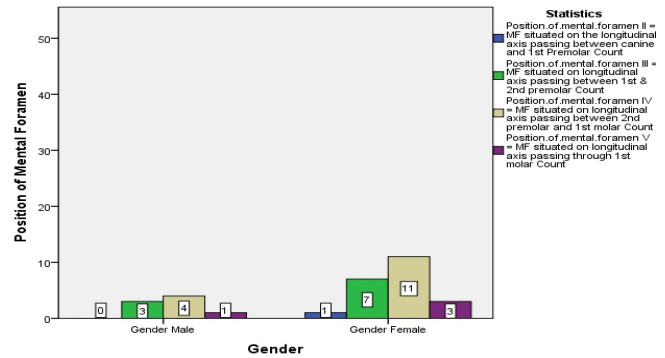


Figure 4: shows the frequency of the location of mental foramen between the genders.

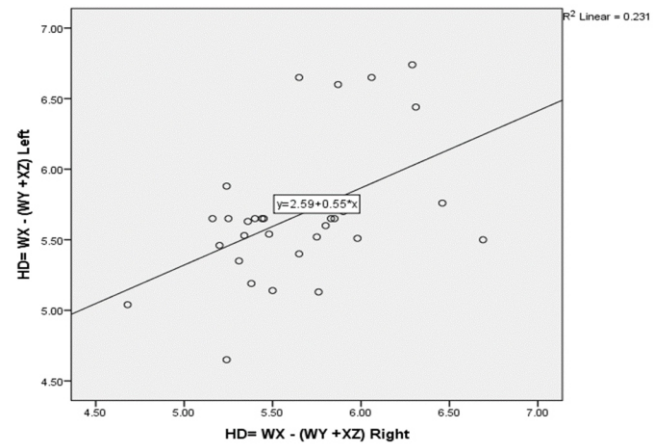


Figure 5: Correlation between HD on right and left side on applying Pearson's correlation

“Mental foramen” is located on mandible's body and is responsible for transmission of “mental nerve and vessels”. Sensory supply to the area of lower lip, buccal mucosa and skin of chin is supplied by the mental nerve³. The accurate anatomical MF position is of utmost importance for administration of anesthesia locally as well as other surgical procedures. Injury to the mental nerve and vessels may lead to serious complications¹⁰ such as total or partial loss of sensations, numbness and bleeding.

DISCUSSION

In our study, shape of the “mental foramen” was oval in 66.7% of mandibles and round in 33.3%. This was in accordance to the study conducted by Sharma (2021)¹¹ who observed 50 dry human

mandibles of either gender in India and found that most frequent occurring was oval shape (68%) on the left side and 62% on the right side in males, whereas, in females 70% and 72% were observed in left and right sides respectively. The results were in accordance with another study¹² using 100 dry human mandibles of unknown gender in Surat, India. Current findings are in disagreement with a previous study done on dry human adult mandibles in India¹³ in which “round shaped mental foramen” were observed on the “right” (94%) and “left sides” (87%).

The current study observed that the most commonly occurring position of “mental foramen” was found in “position IV” (50%) that is present on the “longitudinal axis passing through the 2nd premolar” followed by “position III” (33.3%) which is located on the “longitudinal axis passing between the 1st and 2nd premolars”. Another study⁹ using 105 dry human adult mandibles in North India discovered the shape, position as well as number of “mental foramina”. Most frequently occurring position was found on the “longitudinal axis of second premolar position” (61.0%) on right side while 59.1% was noted on the left side, succeeded by positions III, V, II, and VI. A study conducted on 41 dry adult human mandible by Bala et al (2017)¹⁴ studied the prevalence, shape, position and existence of accessory “mental foramen” in Jammu and Kashmir, India and found that in relation to teeth, the predominant position of foramen was in “line with the longitudinal axis of 2nd premolar on both right (63.42%) and left (60.98%) sides” which were in accordance with the current study. However, a study conducted by McKay et al (2018)¹⁵ in South Africa on 325 dry adult human mandible showed position III, L: 34.78 % / 63.77 % and R: 46.43 % / 62.5 % to be most common among males and position IV, L: 52.17 % / 76.08 % and R: 60.61 % / 69.7 %, in females. A study conducted by Subramanian et al (2019)² in 33 Zambian adult human mandibles demonstrated position V, 51.5% to be most prevalent followed by Position IV, 33.3%. This shows variations in the location of the “mental foramen” in African population.

In this study, mental foramen shape was ovoid, in 66.7% of “mandibles” and “round” in 33.3%. This was similar to the study conducted by Sharma (2021)¹¹ who observed 50 dry human mandibles of either gender in India where most commonly occurring shape was observed to be oval (68%) on the left side and 62% on the right side in males and in female fender 70% on left hand side while 72% on right hand side.

The results were consistent with the study done by Agarwal & Gupta (2011)¹² using one hundred dried mandibles of unknown gender in Surat, India. The results of the current study are contradicting with a previously conducted researches on 100 dry adult human mandibles in India by Singh & Srivastav¹⁷ in which mental foramen was noted to have a round shape on right side (94%) as well as on left sides (87%).

Our study found higher vertical diameter (VD) on the right hand side in comparison to left hand side. Vertical diameter on right

and left sides were found to be 2.64±0.08mm and 2.63±0.06 mm, respectively.

The horizontal diameter (HD) observed was 5.76±0.47 on left hand side and 5.65±0.54 on opposite side. Our results have been similar to those of Budhiraja et al (2013)⁹. Oguz and Bozkir¹⁶ conducted a study in Turkey on 34 dry mandibles and demonstrated “mean HD of 2.93mm on the right side and 3.14mm on the left side”, and a “mean VD of 2.38mm and 2.64mm on the right and left sides, respectively”. Current study data varied remarkably for HD from those of Oguz and Bozkir¹⁶. Singh and Srivastav¹⁷ investigated another study on 100 dry adult human mandibles in India in which only “HD” was noted and the results showed a lower mean value of HD than the current research. This noticeable variation in HD could be due to greater number of round MF than oval in their study.

In this research, correlation of HD and VD was also observed. On the left side, the correlation was found to be weak negative. However, a weak positive correlation was seen between the HD & VD and also in VD on both sides. To the best of our knowledge, this is the first study conducted in Pakistan in which the HD and VD were compared on dry mandibles. Hence, it will provide additional knowledge in accurate localization of MF in terms of its size and position. As for the limitations, the data is based on a small sample size. Therefore, the generalizability of the results to the entire population cannot be justified. Moreover, this study did not determine the gender as it might have affected the results. The current analysis displayed variations of “shape, position and size of mental foramen” that exist among population of Pakistani. Therefore, it is extremely important for surgeons to be aware of the exact precise location of “mental foramen” especially during anaesthesia administration and performing surgeries. Therefore, it is imperative to know its location so that surgical mishaps can be avoided. Location and size of “mental foramen” is also a major aid in the recognition of age, hence the observations found in this study would prove beneficial in forensic anthropology. However, as there is scarcity of the studies on the morphometric analysis of “mental foramen” particularly in determining positions of the foramen, both vertical and horizontal, in dry mandible of Pakistani population further research on larger samples is highly recommended.

CONCLUSION

Based on the results of this study, the most commonly observed shape of mental foramen was oval while position IV was the commonest position observed. Moreover, a positive correlation was observed between the VD on both, the right and left sides. Thereby advocating the use of these measurements prior to surgical procedures.

REFERENCES

1. Mohammed M, Ahmed M, Amani A, Zainab Sa, Nazeeha H, Riyadh A, et al. Structural Features of the Mental Foramen in a

- Saudi Subpopulation: A Retrospective CBCT Study. *Biomed Res. Int.* 2021;7.
- Subramanian B, Anthony SN, Mubbunu L, Hachombwa C, Mlawa MS, Majambo MM, et al. Anthropometrics Analysis of Mental Foramen and Accessory Mental Foramen in Zambian Adult Human Mandibles. *ScientificWorldJournal.* 2019;16.
 - Nanayakkara D, Sampath H, Manawaratne R, Peiris R, Vadysinghe A, Arambawatte K. Positional variation and localization of the mental foramen. *MOJ Anat & Physiol.* 2018;5(1):00162.
 - Bello SA, Adeoye JA, Ighile N, Ikimi NU. Mental Foramen Size, Position and Symmetry in a Multi-Ethnic, Urban Black Population: Radiographic Evidence. *J Oral Maxillofac Res.* 2018;30;9(4):e2.
 - Ukoha UU, KE Umeasalugo, UC Ofoego, OC Ejimofor, HC Nzeako, CG Edokwe. Position, shape and direction of the mental foramen in mandibles in South-Eastern Nigeria. *Int J Biomed Res.* 2013;4(9):499-503.
 - Moiseiwitsch JR. Position of the mental foramen in a North American, white population. *Oral Surgery, Oral Medicine, Oral Pathology, Oral Radiology, and Endodontology.* 1998;85(4):457-60.
 - Hoque MM, Ara S, Begum S, Kamal AM, Momen MA. Study of number, shape, size and position of mental foramen in Bangladeshi dry adult human mandible. *Bangladesh Journal of Anatomy.* 2013;11(1):7-10.
 - Igbigbi PS, Lebona S. The position and dimensions of the mental foramen in adult Malawian mandibles. *West African journal of medicine.* 2005;24(3):184-9.
 - Budhiraja V, Rastogi R, Lalwani R, Goel P, Bose SC. Study of position, shape, and size of mental foramen utilizing various parameters in dry adult human mandibles from north India. *International Scholarly Research Notices.* 2013;2013.
 - Shalash M, Khallaf ME, Ali AR. Position and dimensions of the mental foramen and presence of the anterior loop in the Egyptian population: a retrospective CBCT study. *Bulletin of the National Research Centre.* 2020;44(1):1-6.
 - Sharma N. A morphometric analysis of shape, size and position of mental foramen in dry human mandibles. *Trends Clin. Med. Sci.* 2021;1(1):1-5.
 - Agarwal D, Gupta SB. Morphometric Analysis of Mental Foramen in Human Mandibles of South Gujarat. *People's Journal of Scientific Research.* 2011;4(1):15-18.
 - Singh R, Srivastav AK. Evaluation of position, shape, size and incidence of mental foramen and accessory mental foramen in Indian adult human skulls. *Anatomy. International Journal of Experimental and Clinical Anatomy.* 2011;5(1):23-9.
 - Bala SS, Shahdad S, Bashir S. Morphology and morphometry of mental foramen in dry human mandibles. *International Journal of Research in Medical Sciences.* 2017;5(4):1461.
 - McKay C, Tchokonte-Nana V, Mbajjorgu EF. El Foramen Mental en Mandíbulas Humanas Secas de Adultos Sudafricanos: Un Estudio Anatómico. *International Journal of Morphology.* 2018;36(4):1361-7.
 - Oguz O, Bozkir MG. Evaluation of location of mandibular and mental foramina in dry, young, adult human male, dentulous mandibles. *The West Indian Medical Journal.* 2002;51(1):14-6.
 - Singh R, Srivastav AK. Study of position, shape, size and incidence of mental foramen and accessory mental foramen in Indian adult human skulls. *Int J Morphol.* 2010;28(4):1141-6.

CONFLICT OF INTEREST

Author declared no conflict of interest

GRANT SUPPORT & FINANCIAL DISCLOSURE

Author declared no specific grant for this research from any funding agency in the public, commercial or non-profit sectors

AUTHORS CONTRIBUTIONS

JAA: Conception, Design of the work, Data collection, and Drafting, Reviewed, Final approval, Agreement to be accountable.

AS: Conception, Design of the work, Acquisition, Data Analysis, and Drafting, Reviewed, Final approval, Agreement to be accountable.

ASN: Conception, Design of the work, Interpretation of data for the work, and Drafting, Reviewed, Final approval, Agreement to be accountable.

AQ: Conception, Design of the work, Data collection, and Drafting, Reviewed, Final approval, Agreement to be accountable.

RA: Conception, Design of the work, Data analysis, and Drafting, Reviewed, Final approval, Agreement to be accountable.



This is an Open Access article distributed under the terms of the Attribution Non-Commercial 4.0 International