

# Association between sectorial retinal nerve fiber layer thickness with anatomical variables of Lamina Cribrosa- A comparative study

Ayesha Saba Naz<sup>\*</sup>, Aisha Qamar<sup>1</sup>, Ambreen Surti<sup>1</sup>, Yasmeen Mahar

<sup>1</sup>Department of Anatomy, Bahria University Health Sciences, Karachi, Pakistan

## ABSTRACT

### Objective

To compare sectorial retinal nerve fiber layer thickness (RNFLT) with anterior Lamina Cribrosa depth (ALCD) and Lamina Cribrosa thickness (LCT) in primary open-angle glaucoma (POAG) cases and healthy age-matched controls.

### Methodology

This was a case-control study. Senior ophthalmologist recruited 57 POAG cases and 46 age-matched healthy controls. Calculation of intraocular pressure (IOP) and open angle carried out using Goldmann tonometry and Slit-lamp biomicroscopy with stereoscopic ophthalmoscopy respectively. Extremely precise spectral domain ocular coherence tomography with enhanced depth imaging (EDI-OCT) utilized to determine ALCD, LCT and RNFLT.

### Results

RNFLT in various sectorial regions displayed statistically significant results ( $p$ -value of 0.001) when compared with controls in a case control study. Superior retinal sector revealed the highest ranges of thickness ( $75.50 \pm 9.64 \mu\text{m}$ ), while thin retina was observed in global measurements ( $48.40 \pm 0.84 \mu\text{m}$ ). Enhanced ALCD was seen ( $545.50 \pm 3.53 \mu\text{m}$ ) among 15 POAG cases. Least thickness of LCT documented in the four POAG cases in inferior retinal sector ( $204.57 \pm 79.04 \mu\text{m}$ ).

### Conclusion

Assessments of RNFLT, ALCD and LCT provides valuable knowledge that can be utilized for the management and predicting the course and prognosis of POAG.

**Key words:** Retina, Lamina Cribrosa, Glaucoma, Tonometry, Ocular coherence tomography

\*For Correspondence

**Dr. Ayesha Saba Naz**

Assistant Professor, Department of Anatomy, Bahria University Health Sciences, Karachi

Email:

[ayeshanaz.bumdc@bahria.edu.pk](mailto:ayeshanaz.bumdc@bahria.edu.pk)

Submission date: 8<sup>th</sup> September 2022

Acceptance date: 31<sup>st</sup> September 2023

Publication date: 31<sup>st</sup> December 2023

## INTRODUCTION

Glaucoma is a plethora of visual disorders, whose pathogenesis revolves around the imbalance in the production and drainage of aqueous humor. It is a protracted ocular condition, typically affecting both eyes that occur in middle to advanced age groups.<sup>1</sup> Worldwide it is adding heavily to the prevalence of cases in middle to old aged population.<sup>2</sup> Glaucoma ranks second in causing irreversible loss of vision<sup>3</sup> and POAG is also the second leading cause of blindness worldwide<sup>4</sup> and in Pakistan as well.<sup>5</sup> Glaucoma being an immense factor for disability, in our already socioeconomically affected country; it is adding more financial and health burden in our population. Glaucoma initiates a cascade of deleterious events that lead to glaucomatous optic neuropathy (GON)<sup>5</sup> that causes thinning of RNFLT which ultimately leads to loss of vision.. World over researchers had proved LC to be the site for the initiation to retinal ganglion cell damage and to have strong association with the progression of glaucoma.<sup>6,7</sup>

Glaucoma causes retinal ganglion cell damage<sup>8</sup> that leads to the progression of optic neuropathy, ultimately leading to development of GON. Lamina cribrosa (LC) is the posterior most

part of sclera and is the spot from which the optic nerve exits the globe of the eye, due to which LC appears like a sieve. LC withstands the developing increasing intraocular pressure (IOP), which is the main pathogenesis in glaucoma.<sup>9</sup> Thinner lamina cribrosa thickness (LCT), normal thickness being  $378.1 \pm 117.8 \mu\text{m}$  (median,  $360 \mu\text{m}$ )<sup>10</sup> and deepening of anterior lamina cribrosa depth (ALCD), normal being  $449.3 \mu\text{m}$ <sup>10</sup> had strongly been advocated to be linked with thinner RNFLT<sup>10</sup> (The normal RNFLT measured by Spectral domain ocular coherence tomography (SD-OCT) had been calculated to be around  $100 \mu\text{m}$ <sup>10</sup> by numerous globally conducted studies. Interventional options for glaucoma have been paid more attention rather than focusing towards primary measures of timely screening and halting the progression of glaucoma. LC anatomical measurements, like ALCD and LCT can be an answer to it.<sup>11</sup>

Despite of a high prevalence of POAG in Pakistan, such novel variables had never been researched upon, which could introduce non-invasive tools for timely decision taking in management of POAG and thus it may lessen the burden of disabilities caused by

This article may be cited as: Naz *et al.* Association between sectorial retinal nerve fiber layer thickness with anatomical variables of Lamina Cribrosa- A comparative study. *Adv Basic Med Sci.* 2023; 7 (2) 32-35

this deleterious disease. This work is a pioneer research in regards of studying LC anatomical variables and comparing it with the RNFLT, and expects it to add valuable information regarding new investigatory modalities for POAG

## METHODOLOGY

This case-control study was conducted -at Al-Ain Eye Institute, Karachi, from November 2018 till February 2019 after receiving permission from ERC from Bahria University Medical and Dental College. Sample size of 112 (56 cases and 56 controls) had been planned using “comparing two means” and the estimation of cases was based on the study done by <sup>12</sup> and non-probability purposive sampling technique employed to select the subjects after taking their consent. The cases included had

1. Intraocular pressure (IOP) of >22mmHg measured by Goldmann tonometry (At-900, Haag Striet, Switzerland)
2. Open angle calibrated by Slit-lamp (Topcon SL-D 7, Topcon Corporation, Tokyo, Japan) and stereoscopic ophthalmoscope (WelchAllyn, USA)
3. Had least visual acuity of >20/40

The subjects with other variants of glaucoma, moderate to severe cataract, head trauma, neurological, autoimmune defects, diabetic and hypertensive retinopathies were all excluded from the study.

ALCD and LCT were calculated by EDI-OCT (REVO nx/SOCT Copernicus REVO OPTOPOL Technology, Wavelength 830nm, Axial resolution 2µm, scan speed 1,10,000 scans/sec, scan time 1.37seconds, OPTOPOL Technology Sp. Z o.o, ul. Zabia 42, 42-400 Zawiercie, Poland), with standard guidelines.<sup>12</sup> ALCD was calculated as a line in the middle of the ends of Bruch’s membrane and anterior border of LC. LCT was assessed by measuring the width sandwiched between the anterior and posterior borders of LC.

For Statistical analysis of the study, SPSS version 23 was utilized. Margin of error for sample size calculation was 5% with confidence interval for mean 95%. Kruskal –Wallis test for ALCD and RNFLT were employed. One way ANOVA was used to estimate LCT..p-value of < 0.05 was taken as significant.

## RESULTS

The study included 57 cases of POAG and 46 age-matched healthy controls. 9 respondents were dropped due to poor image quality, obscured view of LC or inability to follow the instructions. Age and gender did not show any significant association with POAG. 56.1% subjects were males and 43.9% were females. Maximum numbers of cases reported were in the age group of 61-70 years. The cases were diverse; some new cases and some were old. Segregation of retina into sectors was according to the standard set by the EDI-OCT into superior, inferior, superior-inferior, nasal, superior, inferior, nasal and global (Table 1).

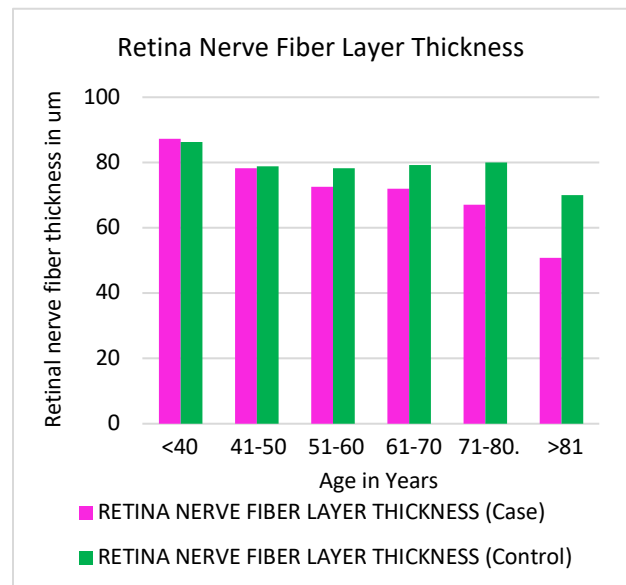
### Estimation of RNFLT in different retinal sectors in POAG cases

Calibration of RNFLT and anatomical parameters of LC were ascertained in the POAG cases (n=57). Majority of the respondents were observed to have superior as well as superior-inferior RNFLT

defects (n=15). Small number of cases (n=2) had shown defects in other sectors of retina. Maximum RNFLT was found out in the superior sector ( $75.50 \pm 9.64 \mu\text{m}$ ), while most thinning was seen in the global RNFL defects ( $48.40 \pm 0.84 \mu\text{m}$ ). Table 1 shows the overall RNFLT which had shown statistically significant result. Maximum LCT was exhibited in the superior-inferior sector ( $226.99 \pm 136.23 \mu\text{m}$ ) which parallels with the RNFLT defect as well, whereas the minimum LCT was found out in the inferior sector ( $204.57 \pm 79.04 \mu\text{m}$ ). Maximum ALCD was shown by the global retinal sector ( $545.50 \pm 3.53 \mu\text{m}$ ) and minimum ALCD observed in inferior defects ( $265.08 \pm 64.51 \mu\text{m}$ ). ALCD and LCT when compared with RNFLT in cases produced insignificant results.

### Retinal nerve fiber layer thickness in different age groups in POAG cases and controls

Such highly significant findings of RNFLT prompted us to explore it in different age groups among the cases and controls. Declining RNFLT can clearly be observed in advanced age groups as shown in figure 1.



## DISCUSSION

Studies regarding the prophylactic approaches in the management of POAG had not been touched upon in Pakistan. LC had been researched worldwide in this context, but in Pakistan it had never been explored. This study can thus be regarded as the first research ever conducted in Pakistan over the anatomical parameters of LC. World over ALCD and LCT had strongly been linked with the onset and progression of glaucoma. LC proves to be an exciting focus directed towards the non-invasive progression measure of POAG. The findings of this study can thus be paralleled with any research conducted worldwide.

It had been documented by researchers worldwide that progression of POAG relates well with waning of RNFLT.<sup>5</sup> Retina is the neuro-sensitive layer of eye involved with the image formation, and retinal ganglion cells are the cells responsible for

Parameters	Superior (n=15)	Inferior (n=4)	No retinal defects in cases (n=19)	Superior and inferior (n=15)	Superior, inferior and nasal (n=2)	Superior, inferior, temporal and nasal (n=2)	p-value
RNFLT ( $\mu\text{m}$ )	75.50 $\pm$ 9.64	67.45 $\pm$ 11.61	82.24 $\pm$ 9.24	67 $\pm$ 13.87	53.10 $\pm$ 8.62	48.40 $\pm$ 0.84	0.001* ¶
ALCD ( $\mu\text{m}$ )	288.86 $\pm$ 83.91	265.08 $\pm$ 64.51	288.27 $\pm$ 138.86	284.1 $\pm$ 59.3	458.83 $\pm$ 431.57	545.50 $\pm$ 3.53	0.410 ¶
LCT ( $\mu\text{m}$ )	205.04 $\pm$ 66.98	204.57 $\pm$ 79.04	226.04 $\pm$ 136.23	223.25 $\pm$ 72.08	226.99 $\pm$ 136.23	214.33 $\pm$ 91.45	0.985 $\circ$

**Table 1:** Evaluation of Sectorial Retinal Nerve Fiber Layer Thickness (RNFLT) With Anterior lamina cribrosa depth (ALCD) and lamina cribrosa thickness (LCT) in Primary Open-Angle Glaucoma (POAG) cases. n=57. p-value of  $\leq 0.05$  is significant and shown with asterisk\*

¶ - Kruskal –Wallis test

$\circ$  - One way ANOVA

NOTE: The retinal nerve fiber global thickness in controls was normal so sectorial RNFLT not shown in the table (78.85  $\pm$  9.01  $\mu\text{m}$ )

Units used:  $\mu\text{m}$ - micrometer

it. With the damage to LC the RNFLT also diminishes.<sup>12</sup> The onset of RNFLT defects precedes the onset of visual field defects.<sup>16</sup> RNFLT defects associates intensely with the decline in sight.<sup>13</sup> This decline in the RNFLT has associations with the changes in LC variables of ALCD and LCT.<sup>14</sup> Our study also elaborated such findings. The superior retinal sector can be seen sustaining most RNFLT defects (n=34) with superior defects occurring alone or in combination with other sectors. Such predilection towards of RNFLT defects in superior retinal sectors have also been observed by Parikh et al.<sup>15</sup> Sectorial superior sector attaining the least thickness in RNFLT observation also matches with other studies.<sup>12</sup> The studies had shown the changes in LC to be closely related with RNFLT.<sup>16</sup> Present study did show the link between the LC variables and RNFLT, but unable to produce significant result which may be attributed due to relatively smaller sample size of POAG cases, and this parameter needs to be further researched in future.

Deterioration in RNFLT had always been accompanied with progression in POAG.<sup>17</sup> The researchers worldwide were prompted to explore the association between the progressions of glaucoma with advancing age. One study authenticates that such decline has a positive connection with age, as younger age groups are proved to have a better RNFLT as compared with older age groups.<sup>18</sup> Studies are in favor of deterioration of glaucoma with progression of age, and document age to be directly proportional to the increase in severity of glaucoma.<sup>19</sup> Some researches do not authenticate such age-wise findings and equates RNFLT defects uniformly in all age groups.<sup>20</sup> Majority of the scholarly research advocates elderly age groups to be having a thinner RNFLT<sup>21</sup>, as our study had also significantly shown.

## CONCLUSION

Assessments of RNFLT, ALCD and LCT provides valuable knowledge that can be utilized for the management and predicting the course and prognosis of POAG.

## Conflict of Interest:

The authors declare no conflict of interest.

## REFERENCES

- Bertaud S, Aragno V, Baudouin C, Labbé A. Primary open-angle glaucoma. *Rev Med Interne*. 2019 Jul 1; 40(7): 445-52.
- Kang JM, Tanna AP. Glaucoma. *Med Clin North Am*. 2021 May 2; 105(3): 493-510. doi: 10.1016/j.mcna.2021.01.004. Epub 2021 Apr 2. PMID: 33926643.
- Sarfraz, M. H., Mehboob, M. A., Ul Haq, R. I. (2017). Correlation between central corneal thickness and visual field defects, cup to disc ratio and retinal nerve fiber layer thickness in primary open angle glaucoma patients. *Pak. J. Med. Sci*. 2017 Feb; 33(1), 132. doi: [10.12669/pjms.331.11623](https://doi.org/10.12669/pjms.331.11623)
- Barnard S. Primary open angle glaucoma. (http://www.barnardlevit.co.uk/assets/Lectures/Glaucoma-POAG-Oslo-2002.pdf)
- Lee EJ, Kim TW, Kim H, Lee SH, Girard MJA, Mari JM. Comparison between Lamina Cribrosa Depth and Curvature as a Predictor of Progressive Retinal Nerve Fiber Layer Thinning in Primary Open-Angle Glaucoma. *Ophthalmol Glaucoma*. 2018 Aug; 1(1): 44-51. doi: 10.1016/j.ogla.2018.05.007. Epub 2018 Jun 29. PMID: 32672632.
- Krzyżanowska-Berkowska P, Czajor K, Helemejko I, Iskander DR. Relationship between the rate of change in lamina cribrosa depth and the rate of retinal nerve fiber layer thinning following glaucoma surgery. *PLoS one*. 2018 Nov 6; 13(11):e0206040.
- Won HJ, Sung KR, Shin JW, Jo YH, Song MK. Comparison of Lamina Cribrosa Curvature in Pseudoexfoliation and Primary Open-Angle Glaucoma. *Am. J. Ophthalmol*. 2021

- Mar 1; 223:1-8.
8. Tan NY, Koh V, Girard MJ, Cheng CY. Imaging of the lamina cribrosa and its role in glaucoma: a review. *Clin Exp Ophthalmol.* 2018 Mar; 46(2):177-88.
  9. Sirakaya E, Kucuk B. Thickness of the lamina cribrosa, retinal-nerve fiber layer, and peripapillary choroid in patients with branch retinal vein occlusion. *Ophthalmologica.* 2020; 243(4):288-96.
  10. Saba A, Usmani A, Islam QU, Assad T. Unfolding the enigma of lamina cribrosa morphometry and its association with glaucoma. *Pak. J. Med. Sci.* 2019 Nov; 35(6):1730.
  11. Kim JA, Kim TW, Weinreb RN, Lee EJ, Girard MJ, Mari JM. Lamina cribrosa morphology predicts progressive retinal nerve fiber layer loss in eyes with suspected glaucoma. *Sci. Rep.* 2018 Jan 15;8(1):1-0.
  12. Kim, Y. W., Jeoung, J. W., Girard, M. J., Mari, J. M., Park, K. H., Kim, D. M. (2016). Clinical assessment of lamina cribrosa curvature in eyes with primary open-angle glaucoma. *PLoS one*, 11(3), e0150260. [doi.org/10.1371/journal.pone.0150260](https://doi.org/10.1371/journal.pone.0150260)
  13. Naz AS, Qamar A, Haque SU, Zaman Y, Faheem F. Association of lamina cribrosa morphometry with retinal nerve fiber layer loss and visual field defects in primary open angle glaucoma. *Pak. J. Med. Sci.* 2020 Mar;36(3):521-525.
  14. Chen A, Cheng YC, Lai HY, Lin PW, Wu PC, Kuo MT, Lai C. The severity of visual field defect and the defective angles of localized retinal nerve fiber layer using a novel approach. *J Formos Med Assoc.* 2021 Dec 1; 120(12):2153-9.
  15. Won HJ, Sung KR, Shin JW, Jo YH, Song MK. Comparison of Lamina Cribrosa Curvature in Pseudoexfoliation and Primary Open-Angle Glaucoma. *Am. J. Ophthalmol.* 2021 Mar 1; 223:1-8.
  16. Parikh R, Kitnarong N, Jonas JB, Parikh SR, Thomas R. Optic disc morphology in primary open-angle glaucoma versus primary angle-closure glaucoma in South India. *Indian J. Ophthalmol.* 2021 Jul; 69(7):1833.
  17. Wu J, Du Y, Li J, Fan X, Lin C, Wang N. The influence of different intraocular pressure on lamina cribrosa parameters in glaucoma and the relation clinical implication. *Sci. Rep.* 2021 May 7; 11(1):1-3.
  18. Alexopoulos P, Fernandes AG, Ghassabi Z, Zambrano R, Lee T, Vellappally A, et al. Lamina Cribrosa Microstructure in Non-Human Primates with Naturally Occurring Peripapillary Retinal Nerve Fiber Layer Thinning. *Investig. Ophthalmol. Vis. Sci.* 2022 Jun 1; 63(7):932-A0401.
  19. Jnawali A, Mirhajianmoghadam H, Musial G, Porter J, Ostrin LA. The optic nerve head, lamina cribrosa, and nerve fiber layer in non-myopic and myopic children. *Exp. Eye Res.* 2020 Jun 1; 195:108041.
  20. Wong BJ, Moghimi S, Zangwill LM, Christopher M, Belghith A, Ekici E, et al. Relationship of Corneal Hysteresis and Anterior Lamina Cribrosa Displacement in Glaucoma. *Am J Ophthalmol.* 2020 Apr; 212:134-143. doi: 10.1016/j.ajo.2019.11.017
  21. Boqoaied FA, Fahmy RM, Al-Hazzaa SA, Qadi N. The Retinal Nerve Fiber Layer Thickness in Patients with Alzheimer's Disease. *Saudi J Med.* 2020 Feb 26; 5(2): 113-129

#### **CONFLICT OF INTEREST**

Author declared no conflict of interest

#### **GRANT SUPPORT & FINANCIAL DISCLOSURE**

Author declared no specific grant for this research from any funding agency in the public, commercial or non-profit sectors



This is an Open Access article distributed under the terms of the [Attribution-NonCommercial 4.0 International](https://creativecommons.org/licenses/by-nc/4.0/)